
Ameloblastoma: from benign to malignant about a case report at the Hospital Center***Soavinandrina Antananarivo (CENHOSOA)***

Fahasoavana Rohamah Njatosoa^{1*}, Jacques Adrien Ramangason¹, Lauricia Gaël Lalanirina¹, Ramarosahanina Harivola Andrianantenaina¹, John Alberto Bam Rakotondrabe², Emmanuel Andrianony Rakotoarivony¹, Aurélien Richard Rakotoarison³.

¹ *Department of Maxillo-facial surgery in University Hospital Center Professor Zafisaona Gabriel Androva (CHU-PZaGa), Mahajanga, Madagascar*

² *Department of Maxillo-facial surgery in University Hospital Center Joseph Dieudonné Rakotovoao (CHU-JDR) – Befelatanana Antananarivo*

³ *Department of Maxillo-facial surgery in Hospital Center Soavinandrina (CENHOSOA), Antananarivo*

Correspondant author : Names :Fahasoavana Rohamah Njatosoa

Adress : Centre Hospitalier Universitaire PZaGa, Androva Majunga Madagascar.

Abstract

Ameloblastoma is a common odontogenic tumor of the maxillae in developing countries such as Africa. It is a benign tumor, but highly invasive, recurrent and potentially malignant. The aim of this study was to share clinical experience of a rare case of ameloblastoma that had become malignant, and to determine the probable causes of this transformation. This is a retrospective study covering a 20-year period from 2002 to 2021. Six cases were identified, but only one met our inclusion criteria. All parameters were reported for comparison with the literature. Our patient was a 48-year-old adult who came to us in 2002 with a recurrence of right mandibular ameloblastoma. A total of six operations were performed on this patient, and on each occasion, the technique adopted was enucleation, which is a conservative surgery. The clinic is characterized by the absence of pain at its onset, becoming painful at the cancerous stage. The initial CT scan suggested well-limited, monogeneodic tissue osteolysis, then mixed polygeodic, then poorly limited with invasion into neighbouring tissues, and finally with lymph node and lung metastases. Chemotherapy was administered, but the patient did not survive. When faced with a

recurrent ameloblastoma, radical surgery of the interrupting osteotomy or non-interrupting type would be the best indication to avoid multi-recurrence and malignant transformation.

Key words: Ameloblastoma, Surgery, Recurrence, Malignant transformation.

INTRODUCTION

The overall aim of this study is to share a clinical experience on a case of historical ameloblastoma that became malignant.

Ameloblastoma is a benign, locally invasive odontogenic epithelial tumour. In 80% of cases, it is located in the posterior mandible. Its annual incidence in the general population is 0.5 cases per 1,000,000 inhabitants, and more frequently in developing countries [1]. This type of tumor is not an emergency pathology, but its seriousness stems from its insidious invasive evolution. Their histopathological types can vary according to the WHO classification. The most common is the follicular plexiform type [2]. Clinically, an ameloblastoma remains asymptomatic and evolves slowly before the discovery of a swelling deforming the face, tooth mobility and/or falls [3]. On radiography, it presents as a uni- or multilocular osteolytic lesion with a cystic and/or tissue-like appearance. Sometimes, intra-lesional bone septa are visible, giving a honeycomb-like appearance [3]. Diagnosis is confirmed anatomically and pathologically [1, 2].

Prognosis depends mainly on how early the disease is diagnosed and managed [3]. Treatment is purely surgical, with a wide excision margin to avoid recurrence, which is very common. Malignant transformation is possible after several recurrences [3, 4].

PATIENT AND METHOD

Our study was carried out at the Stomatology and Maxillofacial Surgery Department of the Soavinandriana Hospital (CENHOSOA) in Antananarivo. This is a rare case report. All the variables mentioned in this case are compared with the data in the literature. Over a study period extending from May 2002 to October 2021, i.e. 20 years, six cases were identified, but only one case met our inclusion criteria. This was the case of a patient with a multi-recurrent ameloblastoma who had undergone iterative surgery at CENHOSOA, and who developed a malignant transformation.

RESULTS

This is a 48-year-old man who presented with a benign mixed variant ameloblastoma with tissue predominance at onset. This patient had several recurrences. Indeed, five recurrences were

observed over 20 years. Right genital swelling was the reason for our patient's consultation. It was painless to palpate and caused facial asymmetry and even significant deformity of the right face. Dental mobility and displacement were also observed at the third recurrence in 2006. In the malignant stage, signs of odynophagia were mentioned. The pathological findings after the fifth operation suggested malignant ameloblastoma with cervical and pulmonary lymph node metastasis.

The following table shows the evolution of our case.

Evolution	2002	2006	2009	2013	2014
Mainspring for consultation	Painless tumefaction of the right genicus	Painless tumefaction of the right goniac angle	Painless tumefaction of the right ramus	Tumefaction of the right maxillary hemi-arcade	Painful tumefaction of the right hemi-face
Clinical features	Functional discomfort Facial asymmetry Painless	dental mobility and displacement -		- Odynophagia - Suspicious sign of malignancy - Chest pain	- Odynophagia - Chest pain
Cervico-facial ultrasound	Mixed voluminous mandibular mass with tissue predominance			Palpable and visible homolateral adenopathies	Submental adénomégaly
Computed tomography	Right latero-mandibular bone lysis	Mixed-content polygeodic osteolysis	Floor and pharyngeal compression	Multiple thoracic nodules	Invasions: - Submental nodes - Right maxillary sinus - Right nasal fossa - Lungs
Histology	Améloblastoma follicular	Améloblastoma follicular	Améloblastoma follicular		Améloblastoma malignant

The management of our case of ameloblastoma was always conservative surgery by enucleation. After diagnosis of malignancy, chemotherapy was received. By the sixth operation, the prognosis had become bleak. This was caused by respiratory distress probably secondary to pulmonary metastasis. Also, chemotherapy was abandoned due to intolerance linked to poor general condition.

DISCUSSION

Embryologically, during genesis, the epithelial cells of the dental follicle differentiate into several cells. The ameloblastic cells in turn disappear physiologically through apoptosis. The persistence of these cells is the origin of ameloblastoma, which develops within a fibrous stroma. It is characterized by being clinically benign locally, but invasive with a high risk of recurrence [5, 6]. Malignant ameloblastoma is defined by the WHO as a tumor that presents architectural features of benign ameloblastoma and cytological signs of malignancy in the primary tumor and/or metastases [7, 8]. Two percent of ameloblastic tumours are at risk of developing into malignancy [9]. It has a characteristic known as "clinical silence", which leads to neglect of patients who only come for consultation at an advanced stage of the tumor, causing aesthetic problems and functional problems such as dysphagia and dysarthria. It should be noted that the presence of pain can be attributed to a possible superinfection or, at worst, to a malignant form of the tumor.

Our case fits the profile of the type described in the literature. Indeed, our patient belongs to the fourth decade of life and is male. The tumor started in the mandible and progressed to the maxilla. It is a follicular ameloblastoma recurring after repeated enucleations. However, although rare, this tumor has become malignant after several recurrences. The odontostomatologist has an important role to play in the early diagnosis of this tumoral pathology. He or she should consider it if mobile or displaced teeth are present, or if an osteolytic image is observed incidentally on an orthopantomogram or CT scan (see figures B, C, D).

Our study has been confirmed in the literature, which suggests an age of onset of between 30 and 50 years [1]. Rammeh reported ameloblastic tumor involvement at the age of 64 [6]. Burcu Senguven reported a case in a 9-year-old child. The age of onset is therefore relative [10]. As for extension to the maxilla, our study corroborates the study done by Faras in 2017 [11]. However, Filizzola and Siriwardena invalidated this result [12, 13].

Our patient is male. In general, there is no significant difference between the genders, whereas the predominance of the male gender is mentioned in a study by Raharison in Antananarivo in 2004 [14], and by Ahlem in Tunisia in 2015 [15]. However, Faras and Li have demonstrated cases to the contrary [11].

Our histo-pathological finding of follicular type is similar to that of Soyele in Nigeria [16]. In contrast, Intapa in Thailand reported a high frequency of the plexiform type in 2017 [17].

The suggestive clinical signs (facial asymmetry, tooth mobility and displacement) were confirmed by Raharison's study [14] (see Figure A). and that of Bel Hadj Hassine in 2017 [9]. Painful lymph node metastases appearing in 2009 were also a sign suggestive of malignancy according to the literature; as was the presence of chest pain evoked in our study, like the case mentioned by Salami in 2018 [18]. Indeed, malignant transformation is rarely evoked by authors, and not all multi-recurrences lead to malignancy as in our study and that of Faras in 2017 [11].

Treatment of this tumor is purely surgical, with a wide margin of resection. For the malignant form, additional cervical lymph node dissection is essential, particularly if lymph node metastases are observed on imaging. The enucleation technique caused recurrent tumor recurrence in our patient. Ruslin in 2018 [19] and Bal in 2016 [20] also adopted this enucleation technique; as did Collins in 2021 [21]. Indeed, the risk of recurrence is high due to the impossibility of exeresis margins in enucleation. Interruptive or non-interruptive radical surgery is indicated in cases of recurrence and for polygeodic forms. According to Amzerin in 2011 [22] and Li in 2019 [23], complementary radiotherapy can give excellent results, and chemotherapy is very well indicated in the case of distant (pulmonary) metastasis. as in our case.

Thus, a healthcare system that promotes in-depth research to find ways of preventing this pathology, and a choice of appropriate surgery to limit recurrence, are essential and fundamental. The completion of this study would improve the attitude of the two main stakeholders, patient and practitioner, towards this pathology.

CONCLUSION

This study reports a rare clinical case of a muti-recurrent ameloblastoma at CENHOSOA Antananarivo, from its benign to malignant stages. The tumor started in the mandible and invaded the maxilla after several recurrences. Although very rarely observed in the literature,

malignant transformation is possible, as in our case. Adjuvant chemotherapy and radiotherapy are then adopted, but the prognosis is guarded at this malignant stage.

Diagnosis is confirmed anatomically and pathologically. The earlier the diagnosis, the earlier the treatment, and therefore the better the prognosis. Treatment should be radical surgery with an interrupting or non-interrupting osteotomy to avoid recurrence.

REFERENCES

1. Reyes GM, Cuello UFC. Malignant ameloblastoma: multiple local recurrence and metastasis in the scalp. *Case reports*. 2019;5(1):36-45.
2. Konate M, Elbouhairi M, Benyahya I. Améloblastome folliculaire de la mandibule : Rapport d'un cas clinique <https://www.lecourrierdudentiste.com/cas-clinique/ameloblastome-folliculaire-de-la-mandibule-rapport-d-un-cas-clinique>. [Consulté le 02 mai 2020].
3. Turki IM, Douggaz A. A histologic variant of ameloblastoma: the acanthomatous type. *Med Buccale Chir Buccale* 2016;22:55-7.
4. Rathore AS, Juneja S, Khurana N, Shetty DC. Papilliferous Keratoameloblastoma: A Rare Case Report. *Int J Appl Basic Med Res*. 2017 Apr-Jun;7(2):139–42.
5. Milman T, Ying GS, Pan W, LiVolsi V. Ameloblastoma: 25 Year Experience at a Single Institution. *Head Neck Pathol*. 2016 Dec;10(4):513–20.
6. Rammeh S, ZermaniR, ZeddiniF, KourdaN, FarahF, Bettaieb E et al. Améloblastome malin : étude d'un cas et revue de la littérature. *Annales de pathologie*. Science Direct. 2004 Nov;24(1):149.
7. Ali M, Bukhari MH, Hassan F, Illyas M. Clinicopathological study of ameloblastoma and detection of human papilloma virus by immunohistochemistry.

-
- Pak J Med Sci. 2019 Nov-Dec; 35(6):1691–6.
8. Nakano K, Takabatake K, Kawai H, Yoshida S. Notch Signaling Affects Oral Neoplasm Cell Differentiation and Acquisition of Tumor-Specific Characteristics. *Int J Mol Sci.* 2019 Apr;20(8):1973.
 9. Bel HHM, Oualha L, Ayachi S. Ameloblastoma: a retrospective study. *Actual. Odonto-Stomatol.* 2017;284: 4.
 10. Sengüven B, Baris E, Oygür T, Öztemel A. Recurrent unicystic mural type ameloblastoma in a 9-year-old boy, 8 years follow-up. *Contemp Clin Dent.* 2013 Oct-Dec;4(4):569–72.
 11. Faras F, Abo-Alhassan F, Israël Y, Hersant B, Meningaud JP. Multi-recurrent invasive ameloblastoma: A surgical challenge. *Int J Surg Case Rep.* 2017;30:43–5.
 12. Filizzola AI, Ribeiro TC, Santos BS, Pires FB. Ameloblastomas: Clinicopathological features from 70 cases diagnosed in a single Oral Pathology service in an 8-year period. *Med Oral Patol Oral Cir Bucal.* 2014 Nov;19(6):e556–1.
 13. Siriwardena BSMS, Tennakoon TMPB, Hunter KD, Tilakaratne WM. Unicystic Ameloblastoma: Analysis of 370 Cases in a Single Center in Sri Lanka. *J Oral Pathol Med.* 2018 Aug;47(7):706-9.
 14. Raharison SA. Problèmes diagnostiques des améloblastomes. *biblio.univ-antananarivo.mg* 2004, Oct [Consulté le 10 Janvier 2022]. http://biblio.univ-antananarivo.mg/pdfs/raharisonsolonomenjanaharya_med_doc_04.pdf.

15. Ahlem B, Wided A, Amani L, Nadia Z, Amira A, Faten F. Study of Ki67 and CD10 expression as predictive factors of recurrence of ameloblastoma. *Eur Ann Otorhinolaryngol Head Neck Dis.* 2015 Nov;132(5):275-9.
16. Soyele OO, Adebiyi KE, Adesina OM, Ladeji AM, Aborisade A. Ameloblastic carcinoma: a clinicopathologic analysis of cases seen in a Nigerian Teaching Hospital and review of literature. *Pan Afr Med J.* 2018 Nov 27;31:208.
17. Intapa C. Analysis of Prevalence and Clinical Features of Ameloblastoma and its Histopathological Subtypes in Southeast Myanmar and Lower Northern Thailand Populations: A 13-Year Retrospective Study. *J Clin Diagn Res.* 2017 Jan;11(1):ZC102-6.
18. Salami A, Ezenkwa U, Salami M, Ajani M, Okolo C. Malignant ameloblastoma: a challenging diagnosis. *Autops Case Rep.* 2018 Sep 26;8(4):e2018043.
19. Ruslin M, Hendra FN, Vojdani A, Hardjosantoso D, Gazali M, Tajrin A et al. The Epidemiology, Treatment, and Complication of Ameloblastoma in East-Indonesia: 6 Years Retrospective Study. *Med Oral Patol Oral Cir Bucal.* 2018 Jan 1;23(1):e54-8.
20. Ba1 B, Singaré DK, Diallo M, Coulibaly AD. L'améloblastome mandibulaire: à propos de 51 cas. *Med Buccale Chir Buccale* 2016;22:7-11.
21. Collins AP, Mubarak N, Hemaidan HS, Hemaidan SM, Hemaidan A. Malignant Ameloblastoma with Hepatic Metastasis in a 38-Year-Old Haitian Woman. *Am J Case Rep.* 2021;22:e929422-1-6.
22. Amzerin M, Fadoukhair Z, Belbaraka R, Iraqui M, Boutayeb S.

Metastatic ameloblastoma responding to combination chemotherapy: case report and review of the literature. *J Med Case Reports*. 2011;5:491.

23. Li D, Xu S, Sun M, Qiao L. MAID chemotherapy regimen as a treatment strategy for metastatic malignant ameloblastoma: A case report. *Medicine (Baltimore)* 2019 Jun; 98(25):e15873.

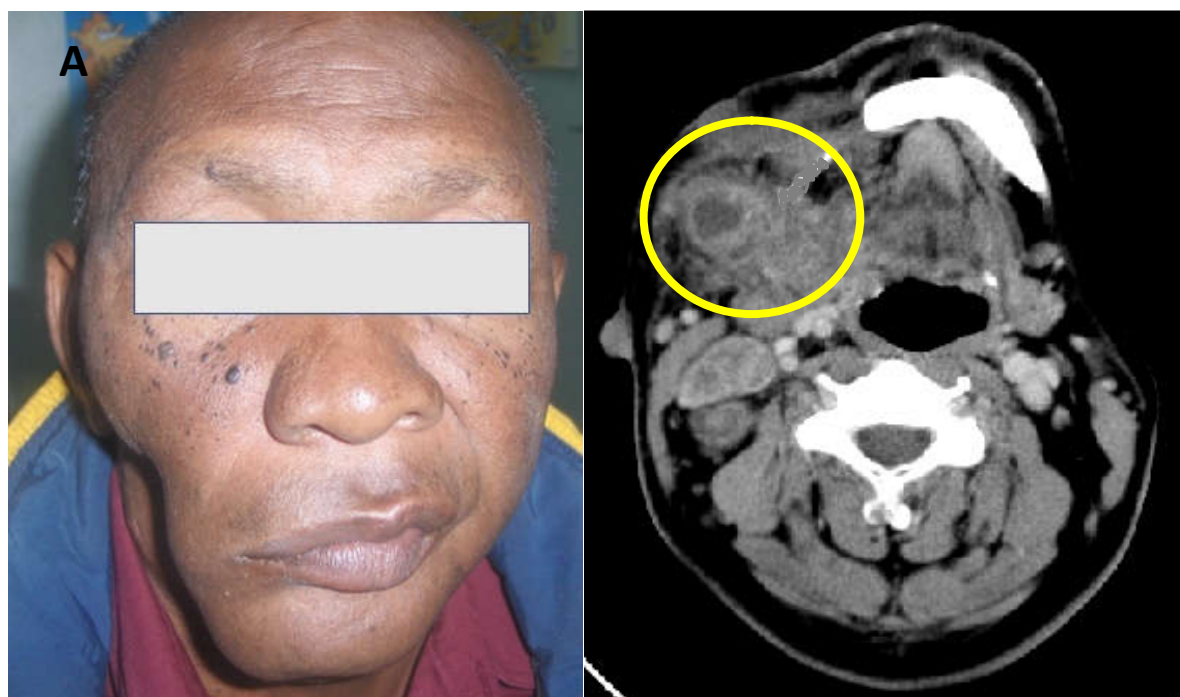


Figure A :asymmetrical patient face on after the other five invasive surgical procedures

Figure B :polygeodic image with mixed fluid content (tissue and fluid)
(CENHOSOA, 2002 à 2006)

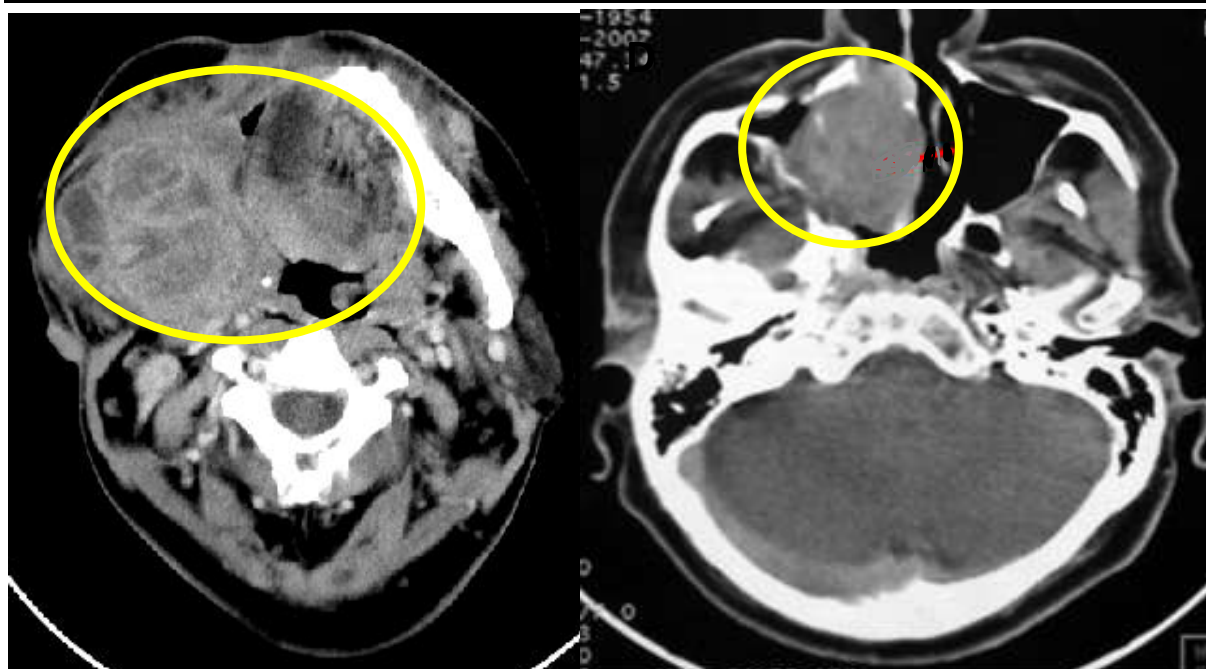


Figure C : reflux or the buccal floor and pharynx with suspicious appearance of malignancy

Figure D :Invasion of maxillary sinus and right nasal cavity

(CENHOSOA, 2009 et 2014)